



PANORAMIC Imaging News

Volume 4, Issue 2

US \$6.00

Editor:

Allan G. Farman, BDS, PhD (odont.), DSc (odont.), Diplomate of the American Board of Oral and Maxillofacial Radiology, Professor of Radiology and Imaging Sciences, Department of Surgical and Hospital Dentistry, The University of Louisville School of Dentistry, Louisville, KY.

Featured Article:

Tooth Eruptions and Dental Impactions

In The Recent Literature:

Prenolar Extraction

Impacted Teeth

Impacted Canines

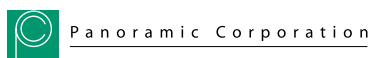Learning Objectives:

Gain understanding of the role of radiography in determining the normality of tooth eruption with regard to positions and time sequence.

Learn about the role of panoramic radiography in identifying and monitoring premature eruption, retarded eruption and dental impactions.

Learn the proper use of panoramic radiography, its benefits and limitations, in reviewing impactions.

Provided as a professional service by:



The Richmond Institute
for Continuing Dental Education

A division of Young Innovations, Inc.

Tooth Eruption and Dental Impactions

By Dr. Allan G. Farman

A broad range of variation exists in the normal eruption times of primary and permanent teeth in humans. However, normality is usually associated with bilateral symmetry. Furthermore, cases where eruption time is grossly beyond the extremes of normalcy may be considered to represent a pathological state [1]. Radiography plays an important part in determining the normality of tooth eruption with regard to position and time sequence. This is particularly important in patients whose teeth are undetectable by clinical means, such as those with delayed eruption or impaction. Impaction is the impeding of the eruption by tooth, bone, or pathosis, so the eruption of the tooth is rendered unlikely.

Premature Eruption

Occasionally, one or two primary teeth – natal teeth – are present at birth or, in the case of neonatal teeth, erupt within the first month of life [2]. Eighty-five per cent of such premature teeth are mandibular primary central incisors, 11 % are primary maxillary incisors, and 4 % are primary posterior teeth [2]. Generally such teeth are well-formed and normal in all respects. They should be retained despite nursing difficulties [3]. Although anecdotally there may be a familial occurrence, most cases defy explanation [4]. A study of 34,457 infants born in southern Finland (1997-2000) determined an incidence of 1:1000 for natal and neonatal teeth and found no association with environmental pollutants [5]. Other studies have put the incidence of natal and neonatal at between 1:700 and 1:3,500 live births with a predilection for occur-

rence in females. [6]. Natal and neonatal teeth are occasionally reported in patients having syndromes such as pachyonychia congenita, Hallerman-Streiff syndrome, and Wiedemann-Rautenstrauch syndrome, the latter being associated with premature aging [7-14]. Radiographic inspection is not necessary.

Premature eruption of a permanent tooth sporadically may follow premature loss of the overlying primary tooth. This can readily be assessed using panoramic radiographs [15]. Caries and restorations in primary teeth have also been associated with premature eruption of their successors [16]. A study of 4,468 Flemish children indicate that the emergence of the maxillary and mandibular premolars was accelerated by 2-8 months when its predecessor had been decayed or restored but had not been extracted. Very early eruption of a permanent tooth following agenesis of its primary predecessor has also been reported [17]. Cases of premature eruption involving the whole permanent dentition have been associated with Proteus syndrome [18].

Retarded Eruption

Delay in dental eruption affecting the whole of one or both dentitions has been associated with various systemic conditions, including rickets, cretinism, and cleidocranial dysplasia [1]. Neonatal illness and postnatal nutrition as well as degree of premature birth have been found to affect the timing of primary tooth eruption [19]. Fibromatosis gingivae may either slow or camouflage eruption due to enlarged hyperplastic gingival tissues with dense connective tissue [20]. If the cause is local (e.g. fibromatosis gingivae, supernu-

"Where there is a systemic cause to delayed eruption, lack of eruptive force can be permanent, and there is no known remedy. Such unimpeded unerupted teeth are termed embedded."

merary tooth, or odontoma), treatment of the primary condition should promote eruption. Excessive delay in eruption should be evaluated using either panoramic or intraoral radiographs. Panoramic radiology will provide the best overview so long as the patient can cooperate for the full exposure time.

Where there is a systemic cause to delayed eruption (e.g. cleidocranial dysplasia), lack of eruptive force can be permanent, and there is no known remedy [21,22]. Such unimpeded unerupted teeth are termed embedded (Fig. 1). In such cases, periodic panoramic radiography is useful to evaluate the possible development of associated pathoses, including dentigerous cysts.

A variety of conditions have been associated with temporary delayed eruption – or delayed dental development. These include low birth weight [23], HIV infection in childhood [24,25], Silver-Russell syndrome [26], Kabuki syndrome [27], osteopetrosis [28], and pycnodysostosis [29]. A study of 70 HIV infected children aged 5 months to 13 years found that delay in tooth eruption is most closely linked to severity of symptoms rather than to CD4 depletion [25].

Dental Impactions

Impacted teeth may be defined as those teeth prevented from eruption due to a physical barrier within the path of eruption. Any tooth can be impacted; however, teeth in the regular permanent dentition or supernumerary teeth are usually affected. A study of radiographs from 3,874 dental patients aged over 20 years determined the prevalence of impaction to be 17 % [30]; hence, this condition can be considered among the most significant affecting dental care. The most frequently affected regular teeth are the third molars (especially in the mandible)

Fig. 1: Multiple unerupted regular permanent and supernumerary teeth in a patient having cleidocranial dysplasia.

Fig. 2: Molar impaction classification according to angulation of the impacted third (and in the case of the horizontal impaction illustrated here – supernumerary/fourth) molar tooth.

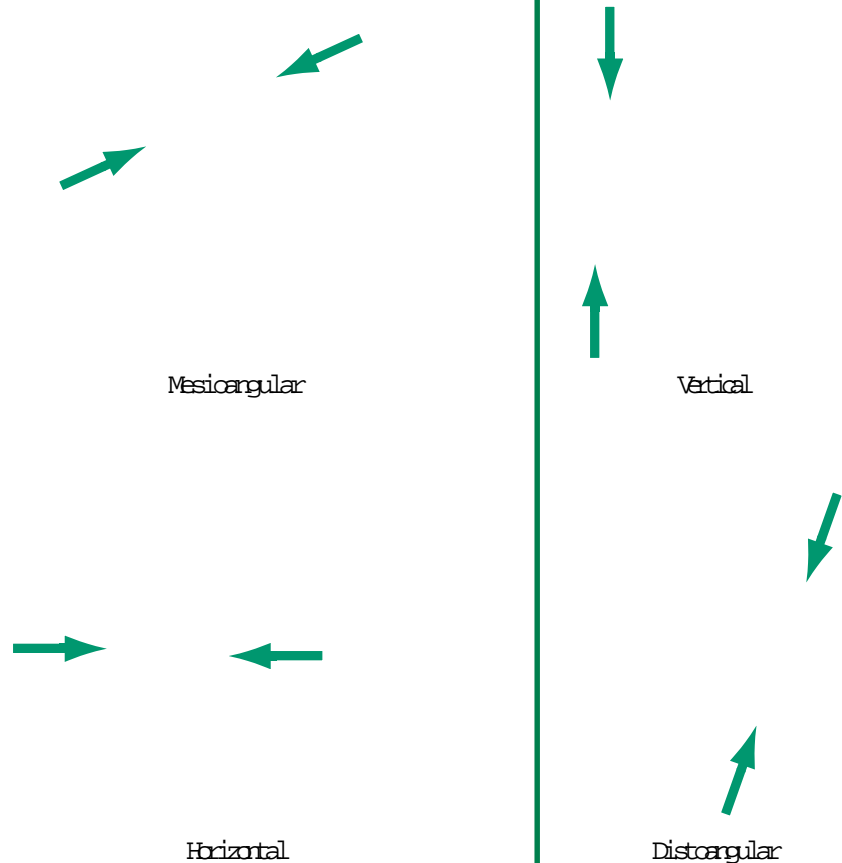
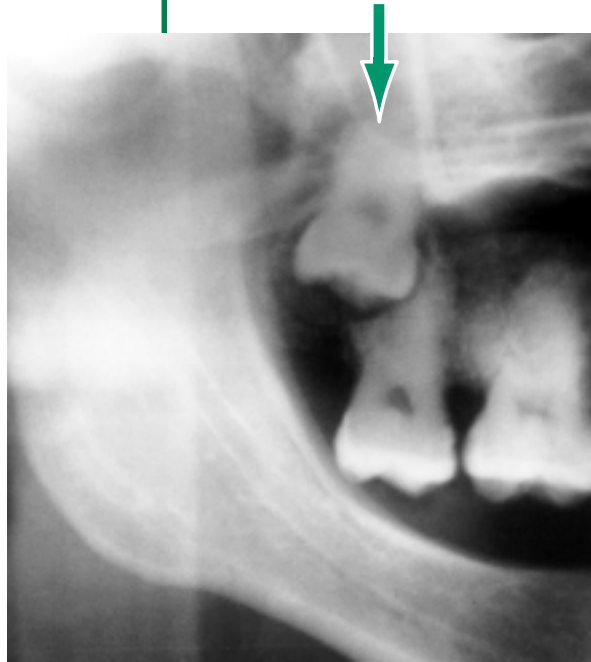

Fig. 3:
Vertically-
impacted
maxillary third
molar tooth.



and the permanent maxillary canines. Cases can occur simply due to dental crowding, to space reduction following premature loss of primary teeth, or to an errant path of eruption.

Third Molars

Impacted mandibular third molars are traditionally classified according to position following the method of Winter [31] (Fig. 2). The most common type of impaction for mandibular molars is mesioangular. Mesioangular-impacted mandibular third molars lie obliquely in bone with the crown slanted in a mesial direction, generally in contact with the distal surface of the ipsilateral second permanent molar. Distoangular impacted third molars lie obliquely in bone with the crown slanted in a distal direction towards the ramus, the roots abutting the distal root of the second molar. Vertical impaction sees the third molar in normal angulation, but prevented

from eruption through impingement on the anterior ramus or distal surface of the second permanent molar tooth. With horizontal impaction, the third molar is positioned horizontally within the mandible with the crown directed towards the distal surface of the second molar. In each of these angular impactions, the third molar can be positioned at various depths within bone, and in relation to the mandibular canal. Panoramic radiographs clearly demonstrate the mesio-distal and vertical position of the impacted tooth, but do not provide details of the bucco-lingual positioning or angulation. This can be remedied in most cases by simply taking a true occlusal radiograph using a size 2 intraoral x-ray film to provide details in the third orthogonal plane. This will be sufficient if the tooth is not superimposed over the mandibular canal or intimately associated with that structure. In the few cases where this occurs and extraction is deemed necessary, the case may warrant more advanced imaging using conventional tomogra-

phy, computed tomography, or cone-beam CT with 3-D reconstruction. Panoramic radiographs do not show bucco-lingual dimensions, so they should be supplemented because this dimension is critical for appropriate treatment planning. Damage to the contents of the mandibular canal can lead to temporary or permanent paresthesia of the ipsilateral side of the lower lip. While this complication may be unavoidable, it is less likely to occur given appropriate radiographic assessment.

A prospective cohort study was performed in Sweden to measure the prevalence of disease in conjunction with mandibular third molars referred for removal [32]. Pericoronitis was found in 64 % of cases, caries in the third molar in 31 %, periodontitis in association with 8 %, caries in the second molar in 5 %, and root resorption of the second molar with 1 % of the molars having pathoses. The odds ratio for disease was highest for distoangular molars (5.8) and for impactions partially covered by soft tissue (6.7). The odds ratio for associated pathoses was between 22 and 34 times higher for molars partially covered by soft tissue than for impactions completely covered by soft or bone tissue. For distoangular molars the odds ratio for associated pathoses was 5 to 12 times higher than for molars in other positions.

Impacted maxillary third molars (Fig. 3) may also be mesioangular, distoangular, vertical, or horizontal in position. In the maxilla, no structure as critical to surgical success as the mandibular canal is present; hence, pre-surgical assessment using panoramic and true occlusal radiography is almost invariably sufficient.

Concerning the treatment of impacted third molars, systematic reviews have generally concluded that, in the absence of association with definite pathoses, it is best not to extract these teeth [33,34]. Fur-

ther, there is little evidence that retention of third molars has any effect on anterior crowding that might undermine orthodontic treatment [35]. Nevertheless, univariate analysis based on removal of 354 mandibular third molars identified increased patient age as a factor that predicted the surgical difficulty of third molar extractions, so delay could have a price if extraction is eventually needed [36]. Other factors ascribed to increased surgical difficulty included bony impaction, depth of tooth within bone, horizontal angulation, proximity to the inferior alveolar canal, male gender, and obesity [36]. When it is decided not to extract impacted third molars, periodic panoramic radiographs should be made to assure that no conditions develop that warrant subsequent surgical intervention.

That periodic re-evaluation may be preferred to extraction of third molars in adolescence is supported by a study of 2,857 third molars assessed at age 18 years, and where 93 % were able to be clinically followed up at age 26 years [37]. Approximately 55 % of the teeth that were not considered impacted by age 18 had erupted by 26 years. Of the teeth considered impacted at age 18, 34 % had fully erupted by age 26. Of the maxillary teeth that were categorized as "impacted" at age 18 years, 36 % had fully erupted by age 26, whereas 26% of the mandibular teeth had done so ($p < .01$). Excluding horizontally-impacted third molars, a substantial proportion of impacted teeth did erupt fully. It can be concluded that radiographically-apparent impaction in late adolescence should not be sufficient grounds for their prophylactic removal in the absence of other clinical indications.

Canines

Impacted permanent maxillary canines occur in 1-2 % of the population [38]. These impactions can occur

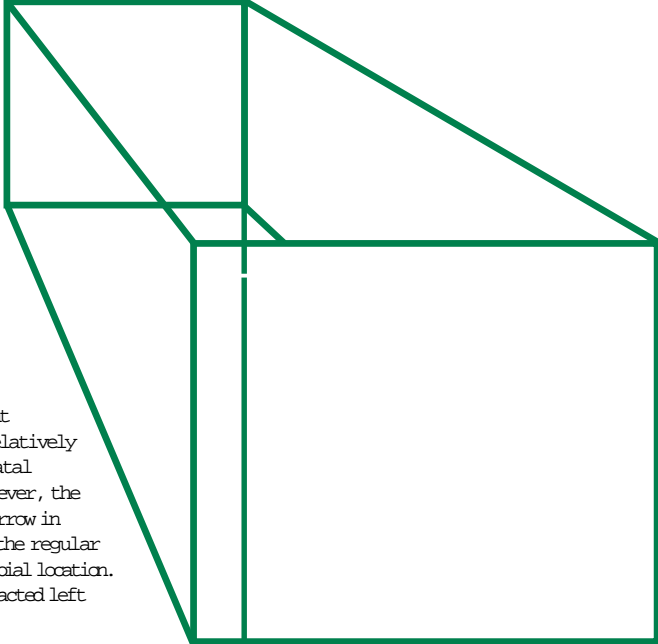


Fig. 4: Impacted maxillary canines. Note that the right canine appears to have a relatively wide crown indicating palatal location of the crown; however, the root appears relatively narrow in comparison with those of the regular teeth indicating a facial/labial location. All bets are off for the impacted left canine due to its rotation.

in different locations. The most important considerations are the relationship of the affected tooth to the erupted regular teeth, especially whether the position of the crown and roots of the impacted tooth is palatal or facial. This determines the surgical access to the maxillary canine impaction for surgical orthodontics or removal.

In more than 60 % of cases of impacted canines it is possible to decide whether the crown of the impacted tooth is facial or palatal using palpation [39]; however, for the remaining one-third, radiographic assessment is needed to effect localization. It was emphasized above that the panoramic radiograph should not be relied on for the assessment of the facio-lingual position of mandibular third molars. In the anterior maxilla, however, it is possible, by using a single panoramic radiograph, to make some inferences regarding the facio-palatal positioning of the impacted tooth with respect to

the erupted regular dentition. This is due to panoramic image layer theory. Objects that are displaced facially with respect to the regular dentition will appear narrowed horizontally, whereas those that are palatally displaced will appear magnified in horizontal dimension (Fig. 4). Hence, if the crown or root of the impacted canine appears broader horizontally in the panoramic image than do the regular tooth crowns or roots, the affected tooth portion is displaced palatally, whereas if it appears narrowed, it is facially positioned. This presupposes that the impacted tooth is morphologically normal in terms of size. It is suggested that localization of impacted canines using panoramic radiographs be supplemented using standard parallax methods employing periapical or occlusal radiographs made at different vertical

"Both regular and supernumerary teeth completely impacted and embedded in bone can occasionally undergo resorption of the root, or crown, or both."

Fig. 5: Any tooth can be impacted.

Impacted
Premolar

Impacted
Incisor

Impacted
2nd Molar

beam angulations for the purpose of verification [40,41].

Unlike the case of the third molar, there are important esthetic reasons for retaining the maxillary canine and bringing it into harmonious alignment with the rest of the dentition. Most cases will be treated by forced orthodontic eruption, often following surgical exposure [42,43]. Treatment time is usually two to three years with more

severely impacted teeth, with younger patients requiring the most time [42]. Successful outcomes are typical [43].

Other Regular Teeth

Regular teeth other than the mandibular third molars and canines are less frequently impacted (Fig. 5). The third most commonly impacted teeth are the premolars in both the mandible and maxilla.

Supernumerary Teeth

A detailed overview of supernumerary teeth was made in a previous issue of *Panoramic Imaging News* (Volume 3; Issue 1). Many supernumerary teeth are impacted or lead to impaction of regular teeth. While these can be detected using panoramic radiography even in the anterior segment the panoramic radiograph does not provide a means of determining the facio-lingual relationship of such teeth to the regular dentition. Supernumerary teeth vary too widely in size and morphology for any panoramic assessment of position because of the effects of tooth magnification with panoramic radiographs.

Resorption of Impacted Teeth

Both regular and supernumerary teeth completely impacted and embedded in bone can occasionally undergo resorption of the root, or crown, or both. In a study of 226 impacted teeth showing resorption, 78 % were in the maxilla, and of the maxillary cases, 60 % were canines [44]. Examination of panoramic radiographs of 11,598 patients (average age 47 years) revealed 1,756 patients having 3,702 impacted teeth with an average retention period approximately 27 years. In these cases, internal resorption was found in 16 (0.43 %) [45] (Fig. 6).

Fig. 6: Detail of resorption of an impacted mandibular third molar tooth.

Pathosis and Impaction

A retrospective study of patients hospitalized for infections associated with partially-erupted third molars from 1985-94 showed the incidence of serious orofacial infections associated with partially-erupted third molars to be 0.016 cases per year per 1000 patients at risk [46]. The same investigation determined the incidence of large third-molar-associated cystic lesions requiring hospitalization to be 0.016 cases per year per 1000 patients at risk [47].

" Within the jaws, teeth are occasionally displaced so that they are mispositioned in the dental arch (transposition), or erupt into even more dramatically anomalous positions."

The presence of mandibular third molar impactions has also been found to be a significant predisposing factor for mandibular angle fractures during injury [48].

Cause-and-effect, or sequence of events, can be difficult to determine. In some cases, impacted teeth develop dentigerous cysts [45,49,50] (Fig. 7). Upon panoramic follow-up, these have been reported to have regressed, only infrequently [49]. Surgical removal of the cystic lesion is the current treatment of choice. Following formation of the cyst, the affected tooth can be displaced considerably as the cyst grows. Of 3,702 impacted teeth retained over an average period of approximately 27 years, dentigerous cystic changes occurred in about 30 (0.81%) [45]. A variety of additional pathoses can cause – or be associated with – impaction and displacement of teeth (Fig. 8). These include the ameloblastoma, odontogenic keratocyst, odontomas, adenomatoid odontogenic tumor [50-53] and, less commonly, ameloblastic fibroma [54] and other cysts and neoplasms.

Ectopic Dental Eruption

Within the jaws, teeth are occasionally displaced so that they are mispositioned in the dental arch (transposition), or erupt into even more dramatically anomalous positions. The prevalence of ectopic eruption of the first permanent molars in a group of 4,232 Thai students, age 6 to 9 years was found to be 0.75% [55]. Transposition has been reported also in the anterior arches [56-57]. Teeth appearing perfectly normal can also be formed at distant sites in the body, such as the ovaries in teratomas [58], but, needless to state, panoramic radiography does not work in such situations!

Concluding Remarks

While there is some controversy concerning the correct strategy to

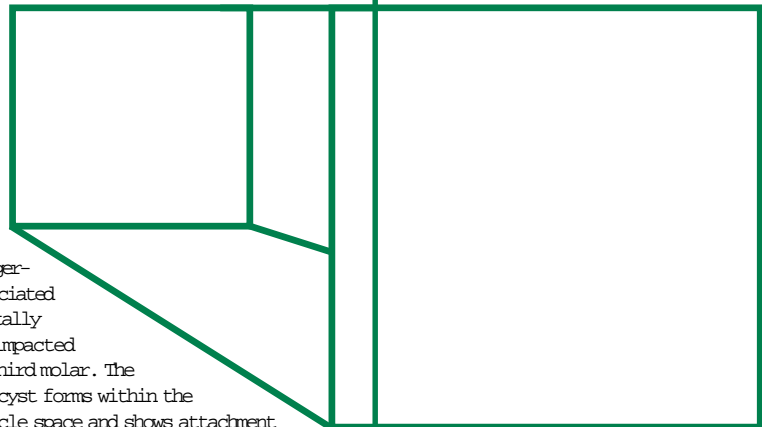


Fig. 7: Dentigerous cyst associated with horizontally positioned impacted mandibular third molar. The dentigerous cyst forms within the dental follicle space and shows attachment at the enamel-cemental junction.

Ameloblastoma

Ameloblastic Fibroma

Fig. 8: Several different pathoses can be associated with dental impactions and tooth displacement. Examples shown here are of ameloblastoma, ameloblastic fibroma, odontogenic keratocyst, and a malignant neoplasm, mesenchymal chondrosarcoma. All four of these examples displace unerupted teeth. All four need histologic analysis of tissue specimens to derive the correct diagnosis.

Odontogenic Keratocyst

Mesenchymal Chondrosarcoma

follow in watching or removing apparently impacted third molars, it is indisputable that the panoramic radiograph provides a valuable means of assessing these teeth. The panoramic radiograph provides informa-

tion only in the vertical and mesio-distal planes, so additional radiographs might be necessary to establish bucco-lingual relationships between teeth and associated anatomic structures.

References

- Shافر WG, Hine MK, Levy BM. A Textbook of Oral Pathology, ed 4. Philadelphia:WB Saunders, 1983; p.59,64.
- Neville BW, Damm DD, Allen CM, Bouquet JE. Oral and Maxillofacial Pathology. Philadelphia: WB Saunders, 1995:63.
- Kaur P, Sharma A, Bhuller N. Conservative management of a complication of neonatal teeth: a case report. *J Indian Soc Pedod Prev Dent.* 2003;21:27-29.
- Asquinazi ML, Pouezet JA, Jasmin JR. Multiple natal teeth and oligodontia: a case report. *Refuat Hapeh Vehashinayim.* 2001;18(3-4):10-2,107.
- Alaluusua S, Kiviranta H, Leppaniemi A, Holtta P, Lukinmaa PL, Lope L, Jarvenpaa AL, Renlund M, Toppari J, Virtanen H, Kaleva M, Vartiainen T. Natal and neonatal teeth in relation to environmental toxicants. *Pediatr Res* 2002;52:652-655.
- Groeneveld X, van Damme P. (Neo)natal tooth in perspective. Literature review and report of two cases. *Ned Tijdschr Tandheelkd.* 1993;100:49-51.
- Strober BE. Pachonychia congenita, type II. *Dermatol Online J* 2003;9(4):12.
- Koenig R. Teebi hypertelorism syndrome. *Clin Dysmorphol.* 2003;12:187-189.
- Hou JW. Hallermann-Streif syndrome associated with small cerebellum, endocrinopathy and increased chromosomal breakage. *Acta Paediatr.* 2003;92:869-871.
- Nicholson AD, Menon S. Hallerman-Streif syndrome. *J Postgrad Med.* 1995;41: 22-23. 11. Korniszewski L, Nowak R, Okniska-Hoffmann E, Skorka A, Gieruszczak-Bialek D, Sawadro-Rochowska M. Wiedemann-Rautenstrauch (neonatal progeroid) syndrome: new case with normal telomere length in skin fibroblasts. *Am J Med Genet* 2001;103:144-148.
- Pivnick EK, Angle B, Kaufman RA, Hall BD, Pitukcheewanont P, Hersh JH, Fowlkes JL, Sanders LP, O'Brien JM, Carroll GS, Gunther WM, Morrow HG, Burghen GA, Ward JC. Neonatal progeroid (Wiedemann-Rautenstrauch) syndrome: report of five new cases and review. *Am J Med Genet.* 2000 Jan 17;90(2):131-40.
- Mandal AK. Primary congenital glaucoma and erupted teeth (natal teeth) in the newborn: a report of two cases. *Ophthalmic Surg Lasers*;32:419-421.
- Balci S, Guler G, Kale G, Soylemezoglu F, Besim A. Mohr syndrome in two sisters: prenatal diagnosis in a 22-week-old fetus with post-mortem findings in both. *Prenat Diagn.* 1999;19:827-831.
- Czecholinski JA, Kahl B, Schwarze CW. Early deciduous tooth loss—the mature or immature eruption of their permanent successors. *Fortschr Kieferorthop.* 1994;55:54-60.
- Leroy R, Bogaerts K, Lesaffre E, Declerck D. Impact of caries experience in the deciduous molars on the emergence of the successors. *Eur J Oral Sci.* 2003;111:106-110.
- Turnbull NR, Lai NN. Eruption of a permanent mandibular canine in a 5-year-old boy. *Int J Paediatr Dent.* 2003;13:117-120.
- Becktor KB, Becktor JP, Karnes PS, Keller EE. Craniofacial and dental manifestations of Proteus syndrome: a case report. *Cleft Palate Craniofac J.* 2002; 39:233-245.
- Viscardi RM, Romberg E, Abrams RG. Delayed primary tooth eruption in premature infants: relationship to neonatal factors. *Pediatr Dent* 1994;16:23-28.
- Huang JS, Ho KY, Chen CC, Wu YM, Wang CC, Ho YP, Liu CS. Collagen synthesis in idiopathic and dilantin-induced gingival fibromatosis. *Kaohsiung J Med Sci.* 1997;13:141-148.
- Unger S, Mornet E, Mundlos S, Blaser S, Cole DE. Severe cleidocranial dysplasia can mimic hypophosphatasia. *Eur J Pediatr* 2002;161:623-626.
- Seow WK, Hertzberg J. Dental development and molar root length in children with cleidocranial dysplasia. *Pediatr Dent* 1995;17:101-105.
- Liu X, Sun Z, Neiderhiser JM, Uchiyama M, Okawa M. Low birth weight, developmental milestones, and behavioral problems in Chinese children and adolescents. *Psychiatry Res* 2001;101:115-129.
- Fine DH, Tofsky N, Nelson EM, Schoen D, Barasch A. Clinical implications of the oral manifestations of HIV infection in children. *Dent Clin North Am.* 2003; 47(1):159-174,xi-xii.
- Hauk MJ, Moss ME, Weinberg GA, Berkowitz RJ. Delayed tooth eruption: association with severity of HIV infection. *Pediatr Dent* 2001;23:260-262.
- Bergman A, Kjellberg H, Dahlgren J. Craniofacial morphology and dental age in children with Silver-Russell syndrome. *Orthod Craniofac Res* 2003;6:54-62.
- Petzold D, Kratzsch E, Opitz Ch, Tinschert S. The Kabuki syndrome: four patients with oral abnormalities. *Eur J Orthod* 2003;25:13-19.
- Dupuis-Girod S, Corradini N, Hadj-Rabia S, Fournet JC, Faivre L, Le Deist F, Durand P, Doffinger R, Smahi A, Israel A, Courtois G, Brousse N, Blanche S, Munnich A, Fischer A, Casanova JL, Bodemer C. Osteopetrosis, lymphedema, anhidrotic ectodermal dysplasia, and immunodeficiency in a boy and incontinentia pigmenti in his mother. *Pediatrics.* 2002;109(6):e97.
- Soliman AT, Ramadan MA, Sherif A, Aziz Bedair ES, Rizk MM. Pycnodysostosis: clinical, radiologic, and endocrine evaluation and linear growth after growth hormone therapy. *Metabolism* 2001;50:905-911.
- Dachi SF, Howell FV. A survey of 3,874 routine full-month radiographs. II. A study of impacted teeth. *Oral Surg* 1961;14:1165-1169.
- Winter GB. Principles of Exodontia as Applied to the Impacted Third Molar. St Louis: American Medical Book Company, 1926.
- Knutsson K, Brehmer B, Lysell L, Rohlin M. Pathoses associated with mandibular third molars subjected to removal. *Oral Surg Oral Med Oral Pathol Oral Radiol Endod* 1996;82:10-17.
- Edwards MJ, Brickley MR, Goodey RD, Shepherd JP. The cost, effectiveness and cost effectiveness of removal and retention of asymptomatic, disease free third molars. *Br Dent J* 1999;187:380-384.
- Hicks EP. Third molar management: a case against routine removal in adolescent and young adult orthodontic patients. *J Oral Maxillofac Surg* 1999;57:831-836.
- Song F, O'Meara S, Wilson P, Golder S, Kleijnen J. The effectiveness and cost-effectiveness of prophylactic removal of wisdom teeth. *Health Technol Assess* 2000;4(15):1-55.
- Renton T, Smeeton N, McGurk M. Factors predictive of difficulty of mandibular third molar surgery. *Br Dent J* 2001;190:607-610.
- Kruger E, Thomson WM, Konthasinghe P. Third molar outcomes from age 18 to 26: findings from a population-based New Zealand longitudinal study. *Oral Surg Oral Med Oral Pathol Oral Radiol Endod* 2001;92:150-155.
- Richardson G, Russell KA. A review of impacted permanent maxillary cuspids—diagnosis and prevention. *J Can Dent Assoc.* 2000;66:497-501.
- Smaliene D. Localization of impacted maxillary canines by palpation and orthopantomography. *Medicina (Kaunas)* 2002;38:825-829.
- Mason C, Papadakou P, Roberts GJ. The radiographic localization of impacted maxillary canines: a comparison of methods. *Eur J Orthod* 2001;23:25-34.
- Jacobs SG. Radiographic localization of unerupted teeth: further findings about the vertical tube shift method and other localization techniques. *Am J Orthod Dentofacial Orthop* 2000;118:439-447.
- Stewart JA, Heo G, Glover KE, Williamson PC, Lam EW, Major PW. Factors that relate to treatment duration for patients with palatally impacted maxillary canines. *Am J Orthod Dentofacial Orthop* 2001;119:216-225.
- Caminiti MF, Sandor GK, Giambattistini C, Tompson B. Outcomes of the surgical exposure, bonding and eruption of 82 impacted maxillary canines. *J Can Dent Assoc* 1998;64:572-9.
- Stafne EC, Austin LT. Resorption of embedded teeth. *J Am Dent Assoc* 1945;32:1003-1009.
- Stanley HR, Alattar M, Collett WK, Stringfellow HR Jr, Spiegel EH. Pathological sequelae of "neglected" impacted third molars. *J Oral Pathol* 1988;17:113-117.
- Berge TI. Incidence of infections requiring hospitalization associated with partially erupted third molars. *Acta Odontol Scand* 1996;54:309-313.
- Berge TI. Incidence of large third-molar-associated cystic lesions requiring hospitalization. *Acta Odontol Scand* 1996;54:327-331.
- Yamada T, Sawaki Y, Tohnai I, Takeuchi M, Ueda M. A study of sports-related mandibular angle fracture: relation to the position of the third molars. *Scand J Med Sci Sports* 1998;8:116-119.
- Shah N, Thuau H, Beale I. Spontaneous regression of bilateral dentigerous cysts associated with impacted mandibular third molars. *Br Dent J* 2002;192:75-76.
- Ikeshima A, Tamura Y. Differential diagnosis between dentigerous cyst and benign tumor with an embedded tooth. *J Oral Sci* 2002;44:13-17.
- Philipsen HP, Reichart PA. Unicystic ameloblastoma. A review of 193 cases from the literature. *Oral Oncol* 1998;34:317-325.
- Tsukamoto G, Makino T, Kikuchi T, Kishimoto K, Nishiyama A, Sasaki A, Matsumura T. A comparative study of odontogenic keratocysts associated with and not associated with an impacted mandibular third molar. *Oral Surg Oral Med Oral Pathol Oral Radiol Endod* 2002;94:272-275.
- Liu JK, Hsiao CK, Chen HA, Tsai MY. Orthodontic correction of a mandibular first molar deeply impacted by an odontoma: a case report. *Quintessence Int* 1997;28:381-385.
- McGuinness NJ, Faughnan T, Bennani F, Connolly CE. Ameloblastic fibroma of the anterior maxilla presenting as a complication of tooth eruption: a case report. *J Orthod* 2001;28:115-118.
- Chintakanon K, Boonpinon P. Ectopic eruption of the first permanent molars: prevalence and etiologic factors. *Angle Orthod* 1998;68:153-160.
- Alaejos-Algarra C, Berini-Ayres L, Gay-Escoda C. Transmigration of mandibular canines: report of six cases and review of the literature. *Quintessence Int* 1998;29:395-398.
- Shapira Y, Kufnec MM. Maxillary tooth transpositions: characteristic features and accompanying dental anomalies. *Am J Orthod Dentofacial Orthop* 2001;119:127-134.
- Main DM. Tooth identity in ovarian teratomas. *Br Dent J* 1970;129:328-332.

In The Recent Literature:

Orthodontics: Premolar extraction reduces the probability of third molar impaction.

Kim TW, Artun J, Behbehani F, Artese F. Prevalence of third molar impaction in orthodontic patients treated nonextraction and with extraction of 4 premolars. Am J Orthod Dentofacial Orthop 2003;123:138-145. [From the Department of Orthodontics, College of Dentistry, Seoul National University, Seoul, Korea.]

This study tested the hypothesis that premolar extraction treatment is associated with mesial movement of the molars concomitant with an increase in the eruption space for the third molars, thereby reducing the frequency of third molar impaction. Panoramic or periapical radiographs, lateral cephalograms, and study models made before (T1) and after (T2) treatment and a minimum of 10 years postretention (T3) of 157 patients were selected from the Department of Orthodontics of the University of Washington, Seattle. Treatment for 105 patients included extraction of four premolars; the other 53 (controls) had been treated without extraction. Student t tests were applied to the data for statistical comparison. For the controls, third molar impaction was found to be more common than in patients who had undergone premolar extraction ($p < .01$), there was less mesial movement of the molars from T1 to T2 ($p < .01$), and a smaller retromolar space was found on average at T2 ($p < .001$) in both arches. Moreover, molar movement was more mesial from T1 to T2 both in the maxilla ($p < .01$) and in the mandible ($p < .05$), and the retromolar space was larger in both arches ($p < .001$) of the patients with eruption than in those with impaction of third molars.

The results support the hypothesis that premolar extraction reduces the frequency of third molar impaction due to increased eruption space afforded by mesial movement of the molars during space closure.

Impacted teeth: Panoramic radiographs revealed impacted teeth in more than 28 % of the study population in Hong Kong.

Chu FC, Li TK, Lui VK, Newsome PR, Chow RL, Cheung LK. Prevalence of impacted teeth and associated pathologies—a radiographic study of the Hong Kong Chinese population. Hong Kong Med J 2003;9:158-163. [From Prince Philip Dental Hospital Faculty of Dentistry, The University of Hong Kong.]

The records of 7,486 patients were examined and a total of 2,115 (28 %) patients were determined to have at least one impacted tooth. The prevalence of impacted teeth was high, with a predilection for impacted third molars in the mandible. As more than 50% of maxillary third molars had erupted in patients having impacted mandibular third molars, this created potential trauma to the pericoronal tissues overlying the impacted mandibular third molars. Roughly one-third of patients with dental impaction reported associated symptoms. Of a total of 3,853 impacted teeth, mandibular third molars were the most frequent (83 %), followed by maxillary third molars (16 %), and maxillary canines (1 %). Some 8 % of mandibular second molars associated with impacted third molars had periodontal bone loss of more than 5 mm on their distal surfaces. Caries were also found on the distal surface of 7% of the associated second molars. Caries

and periodontal diseases were commonly seen in relation to the impacted third molars, yet cystic pathoses and root resorption were rarely observed.

Impacted canines: The probability of impaction of a maxillary canine is very high when the canine overlaps the midline of the lateral incisor.

Warford JH Jr, Grandhi RK, Tira DE. Prediction of maxillary canine impaction using sectors and angular measurement. Am J Orthod Dentofacial Orthop. 2003; 124:651-655. [From the Department of Orthodontics and Dentofacial Orthopedics, University of Missouri, USA.]

Maxillary canine impaction has an incidence of 1 in 100 in the general population. Because patients with canine impactions generally have relatively long orthodontic treatment times, early identification of impaction is of importance to the orthodontist. In this investigation, angulation of the unerupted canine was measured from panoramic radiographs and added to sector location to see whether the combination of these factors could predict impaction more accurately than sector alone. Logistic regression analysis determined that once the canine overlaps the midline of the lateral incisor, there is a greater than 0.87 chance of impaction. Sector location was found to be the better predictor of impaction, with angulation providing little supplementary predictive value.

©2004 Panoramic Corporation (4-04)

Provided as a professional service by:



Panoramic Corporation
4321 goshen road, fort wayne, in 46818 • 800.654.2027

In conjunction with

The Richmond Institute
for Continuing Dental Education

A division of Young Innovations, Inc.

ADAC•E•R•P®
CONTINUING EDUCATION RECOGNITION PROGRAM

The Richmond Institute for Continuing Dental Education is an ADA CERP Recognized Provider.



Academy
of General Dentistry

PACE
Program Approval for
Continuing Education

Approved PACE Program Provider
FAGD/MAGD Credit
10/19/03 to 10/18/07